



PRB expression in stomach of neonate canine without established breed

Expressão de PRB em estômago de neonato canino sem raça definida

Maria Michele Araújo de Sousa Cavalcante^{1*}, Andrezza Braga Soares da Silva¹, Heliana de Barros Fernandes¹, Luana de Oliveira Lopes¹, Ingrid Macedo de Oliveira¹, Helena Lobo Borges², Ana Maria Quessada³, Márcia dos Santos Rizzo¹, Aírton Mendes Conde Junior¹

¹ Department of Morphology, Health Sciences Center, Federal University of Piauí; ² Institute of Biomedical Science, Health Sciences Center, Federal University of Rio de Janeiro; ³ Veterinary Hospital, Paranaense University

ABSTRACT

The cells of the gastrointestinal epithelial mucosa are constantly under high regenerative pressure, due to the expeditious rate of cell turnover in this tissue. To regulate homeostasis in the gastrointestinal tract, a vital balance between cell apoptosis, senescence and the proliferation and differentiation of new cells must be maintained. The present research aim was to analyse the performance of the retinoblastoma protein in different parts of the stomach from neonate dogs. Forty-five canine neonates were used, obtained at private veterinary clinics and Veterinary Hospital of Federal University of Piauí. The animals were obtained from females with dystocia or pregnant, at the end of gestational stage, who had problems during parturition and/or cesarean section whose puppies had died. From these animals were obtained stomach fragments (about 0.5cm) that were fixed in buffered formaldehyde and submitted to histological routine, stained with hematoxylin and eosin, for light microscopy. Then the best blocks were submitted an immunohistochemistry process, using anti-body pRb. The data presented in this paper, strongly suggest that the Rb protein is coupled with apoptosis directly related to the number of cells and renewal of epithelial regulation and gastric mucosa.

KEYWORDS

Immunohistochemistry; Retinoblastoma protein; Neonate canine; Digestive tract; Stomach

RESUMO

As células epiteliais da mucosa gastrointestinal estão constantemente sob alta pressão regenerativa, devido à taxa de renovação celular expressa neste tecido. Para a regulação da homeostase no trato gastrointestinal, um equilíbrio entre a apoptose de células vitais, senescência e a proliferação e diferenciação de células novas tem de ser mantida. A presente pesquisa objetivou analisar o desempenho da proteína retinoblastoma, em diferentes partes do estômago de cães neonatos. Foram utilizados quarenta e cinco recém-nascidos caninos, obtidos em clínicas veterinárias privadas e Hospital Veterinário da Universidade Federal do Piauí. Os animais foram obtidos a partir de fêmeas com distocia ou grávidas no final da fase gestacional, que tiveram problemas durante o parto e / ou cesariana cujos filhotes tinham morrido. A partir desses animais foram obtidos fragmentos do estômago (cerca de 0,5 centímetros) que foram fixadas em formol tamponado e submetidos à rotina histológica, corados com hematoxilina e eosina, para microscopia de luz. Em seguida, os melhores blocos foram submetidos a processo de imuno-histoquímica, utilizando anticorpo pRb. Os dados apresentados neste documento, sugerem fortemente que a proteína Rb é acoplada com a apoptose diretamente relacionadas com o número de células e renovação de regulação epitelial da mucosa gástrica.

PALAVRAS - CHAVE

Imuno-histoquímica; Proteína retinoblastoma; Neonato canino; Trato digestivo; Estômago

CORRESPONDING AUTHOR

Maria Michele Araújo de Sousa Cavalcante <mixa_the17@hotmail.com>
Federal University of Piauí - Campi Minister Petrónio Portela - Ininga
Zip Code: 64049-550/Phone: +55 86 3215-5868
Teresina - PI

INTRODUCTION

The stomach has specific endocrine and exocrine roles. The most important function in digestion process is converting the eaten food in a semi-liquid called chyme. To achieve this result, it is necessary a range of chemical processes, enabled by secretion of stomach cells. The organ is formed by invaginations called pits that are composed for different kind, which to divide the stomach in four functional parts: cardia, fundus, body and pyloric regions. Microscopically, the stomach can be cloven in four layers, as typical of cavitory organs, which are disposed from outside to inside in the following order: serous, muscular, submucosa and mucosa with an epithelial tissue lining with epithelial secretory function (GETTY, 1986; SOYBEL, 2005; JUNQUEIRA and CARNEIRO, 2013).

The cells of the gastrointestinal epithelial mucosa are constantly under high regenerative pressure, due to the expeditious rate of cell turnover in this tissue. To regulate homeostasis in the gastrointestinal tract, a vital balance must be maintained between cell apoptosis, senescence and the proliferation and differentiation of new cells (BRITTAN and WRIGHT, 2003). Programmed cell death (apoptosis) is essential to the development and homeostasis of organisms, and also an important defense mechanism, as the elimination of damaged cells enhances the survival of an organism (CHAU et al., 2002).

Retinoblastoma (Rb) is the main locking mechanism of cell cycle progression, cells only proliferate if the Rb protein is inactivated by phosphorylation through cyclin-dependent kinases (CKD), in particular the complex of cyclin D / CDK4 (ZHU et al., 2005). It is now known that several molecules, which bind to the Rb protein, are involved in cell cycle regulation, coordinating the proliferation, differentiation and cell death (MORRIS and DYSON, 2001).

The neonate morphologic analysis has the same importance of the adult morphologic analysis (DYCE et al., 2010), as well as the understanding of its cell biology. The gestational period is a stage of animal development relevant to veterinary medicine, once it is when morphological and physiological changes are diagnosed, and its study allows the establishment of direct relationships between various diseases and prenatal period (BARRETO, 2003). Therefore, morphologic data about neonate organs generate applicable knowledge in methods of assessing fetal (PASSOS, 2006).

There are few studies about neonate canine digestive tract, and taking in account that stomach is a key organ in the animal development and survival. Considering that are scarce data related to morphophysiological of neonate canine stomach, the aim of this study was to

analyses the performance of the retinoblastoma protein in different parts of the stomach from neonate dogs.

MATERIAL AND METHODS

This study was conducted at the Federal University of Piauí (UFPI), in the Health Sciences Center, Department of Morphology. Were used forty-five mongrel neonates dogs (*Canis familiaris*) obtained by private veterinary clinics of Teresina, Piauí, and the Veterinary Hospital of UFPI. The animals were obtained already dead from dystocic parturition or from pregnant dog with problems in the end of gestational stage. These animals were taken into the Histology and Embryology laboratory of UFPI, to be washed with physiological solution and then they were weighted in a precision digital scale. After identification, the neonates were dissected and the stomach was removed.

Stomach fragments (0.5cm thickness) were obtained from the four portions of the organ and immediately immersed in a sodium hydroxide-buffered 10% formaldehyde (pH around 7.0) solution and fixed for 48 hours. After fixation, the fragments were prepared by histological routine process for light microscopy.

The best blocks were submitted to microtomy and deparaffinized in an oven at 60 ° C with controlled temperature for 1 hour, followed by three xylene bath for five minutes each. Subsequently, sections were hydrated in baths of decreasing concentration alcohol and distilled water. Antigen retrieval was performed using citrate buffer, pH 6.0, for 10 minutes in microwave oven. After this period, the slides underwent two baths of distilled water. The blocking of endogenous peroxidase was performed by immersion of slides in hydrogen peroxide solution 3% diluted in distilled water for 10 to 15 minutes. Soon after, the cuts suffered inhibition of non-specific binding, being subjected to a blocking protein (KitReveal - Biotin-freePolyvalent-Spring), for 10 minutes in a dark humid chamber, to then be incubated with anti-protein pRb primary antibody (SC 50 - Santa Cruz Biotechnology), diluted 1: 400, for 40 minutes at 4 ° C.

Then promoted to amplification using the immunostaining kit avidin - biotin (HRP conjugate, Biogen), in histological sections for 15 minutes. After three washes five minutes each with PBS solution, the samples were developed with the DAB chromogen (3,3-diaminobenzidine). Slides were counterstained with Harris hematoxylin, ending with dehydration of cuts and mounting enthellan and subsequently analyzed by light microscopy. Permanent slides were obtained from the sample cuts, which were analyzed under light microscope (Leica) and photomicrography in digital photomicrography system (MS 2000).

RESULTS AND DISCUSSION

Morphological observations can assist in the understanding of protein dynamics in cells. Thus it was found a cell proliferation on the surface of the cardia region, in addition to surface mucous cells and cells with embryonic characteristics. It was also possible to observe the four regions in which the structure of the stomach is divided, glandular region, submucosa, muscle and outer serous ([Figure 1. Fundus](#)).

In the pyloric region was observed the largest glandular development ([Figure 1. Pyloric](#)) which was the only one region to present glandular formation similar to the glands in an adult animal.

The surface of the canine newborn stomach is irregular, with folds and pleats that suggest anastomosing increase in absorbent area as well as in other animal species

(JUNQUEIRA and CARNEIRO, 2013). These folds are abundant throughout the surface. Note, however, sudden decrease in the region of fundic strips. Due to the reduction of these structures, the bottom is thinner in this region. The body region is very distensible, especially because the area will accommodate the food.

It is known that the Rb gene regulates cell cycle progression, terminal differentiation and programmed cell death (BORGES, 2007). Nuclear labeling immunohistochemistry indicates the presence of the retinoblastoma protein, meaning greater cell control and fewer cells that will go into apoptosis. Thus, according to Dyce et al. (2010), said the fund has a lower pattern of development when compared with other regions of the stomach, marking gathered more strongly present in the fundus specifically in epithelial cells and glandular regions, which shows the strong presence of the Rb protein.

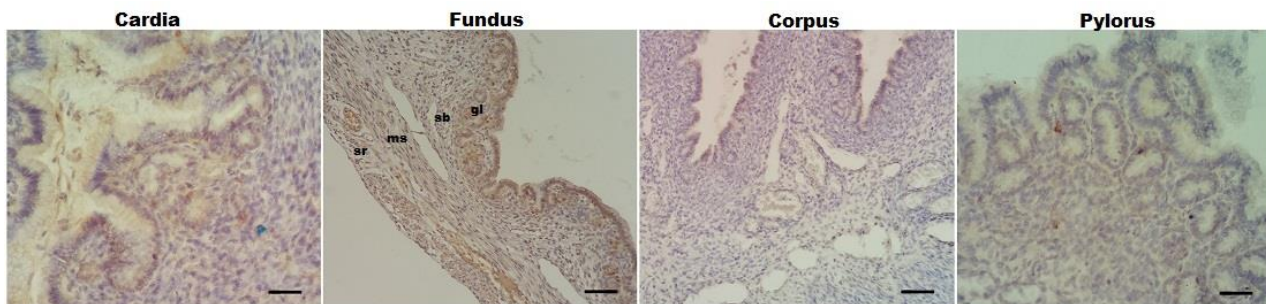


FIGURE 1. Sections of four cross-cutting areas of neonates canine stomach with their immunohistochemistry. Cardia region indicating marking immunohistochemistry (IHC) the epithelium and glands, 400x. Fundic region with the glandular regions (gl), submucosa (sb), muscle (ms) and serous (sr), 200x. Corpus region with point markers of IHC, 200x. Pyloric region highlighting the glandular part, 400x.

The epithelium of the gastrointestinal tract has a highly stereotyped organization with a continuous high level of cell proliferation. The spatial organization of the proliferative compartment is very well defined both in rodents and in man (HALL et al., 1994), in the cardia region of neonate canine, was observed cell proliferation in the surface, indicating an incomplete development stage. The typical crimps in the luminal surface and the gastric mucosa in general forms invaginations in the tunica for the formation of glandular epithelium show that this characteristic indicates incomplete development phase (KARAM, 1998), and it is confirmed by the markings present on the epithelium and glands of the region ([Figure 1. Cardia](#)). Below the gland region there is the submucosa region, which consists of connective tissue, whose collagen fibers are presented in a loosely distributed way, where several mesenchymal cells lie. The presence of these cells in the lamina propria is important to complete the glandular mucosa development, as in this region there is intense hormone production and growth factors that induce

epithelium differentiation (FUKUDA and YASUGI, 2005).

Loss of cells by exfoliation is not a convincing explanation for the massive physiological loss of epithelial cells of the superficial aspect of the gastrointestinal tract, which is then aided by apoptosis. In the stomach and small intestine there is a continuous downward migration of cells from the putative stem cell zones. (SATO and HANSEN, 1992).

Beneddetti et al. (1990) described the occurrence of apoptotic bodies in the duodenal villi and stomach of young rats. The data presented in this paper indicate that apoptosis also occurs in the non-proliferative compartments in a spatially regulated manner. Comparable to the previous reports in relation to cardiac and fundic regions of the neonate, the portions of the body and pylorus are in an advanced stage of differentiation, and the pyloric region is the most improved by not Rb marking ([Figure 1](#)).

The answer to the fact that the pylorus is much more developed than other regions of the stomach is that the entire stomach is derived from the anterior intestine

(OWEN, 1997; CHANDROSOMA and DE MEESTER, 2006a), so the pylorus becomes the first region to start the stomach morphogenesis. Moreover, the main source of gastrin, a hormone directly linked to cell growth and differentiation stomach is the pyloric antrum (KOH et al., 1997). Additionally, the neonate has a hypergastrinemia right after birth, compared with the mother (MOAZ et al., 1983).

The complete process of differentiation occurs only after birth and this is not seen only in dogs (DEREN, 1971), and this event is directly related to distinguished food by which these animals will be submitted after birth (OFUSORI and CAXTON-MARTINS, 2008). It should take into account that food should still be adequate to allow the completion of the development of the stomach, through the aid of nervous and hormonal stimuli (GAMA and ALVARES, 2000).

CONCLUSION

The Rb protein is coupled to apoptosis and directly related to the number of cells and renewal of epithelial regulation and canine gastric mucosa in the neonate. As seen in canine newborn, which has different levels of development in different parts of the stomach when subjected to Rb protein.

REFERENCES

- BARRETO, C. S.; **Avaliação de filhotes caninos**. São Paulo: Universidade de São Paulo; PhD thesis., 2003, 190p.
- BENNEDETTI, A.; MANCINI, R.; MARUCCI, L.; Quantitative study of apoptosis in normal rat gastroduodenal mucosa. **J. Gastroenterol. Hepatol.** v. 5, p. 369-374, 1990.
- BORGES, H. L.; HUNTON, I. C.; WANG, J. Y. J.; Reduction of apoptosis in *Rb*-deficient embryos via *Abl* knockout. **Nature Publishing Group.** v. 26, p. 3868-3877, 2007.
- DEREN, J. S.; Development of structure and function in the fetal and neonate stomach. **The Am. J. Ci. Nutr.** v. 24, p. 144-159, 1971.
- DYCE, K. M.; SACK, W. O; WENSING, C. J. G.; **Tratado de anatomia veterinária**. Rio de Janeiro: Elsevier, 2010. 856p.
- FUKUDA, K.; YASUGI, S.; The molecular mechanisms of stomach development in vertebrates. **Develop Growth Differ.** v. 47, p. 375-382, 2005.
- GAMA, P.; ALVARES, E. P.; Early weaning and prolonged nursing induce changes in cell proliferation in the gastric epithelium of developing rats. **J. Nutr.** v. 130, p. 2594-2598, 2000.
- GETTY, D. V. M.; **Anatomia dos animais domésticos**. Rio de Janeiro: Guanabara Koogan. Rio de Janeiro, 1986. 1458p.

HALL, P. A.; COATES, P. J.; ANSARI, B.; HOPWOOD, D.; Regulation of cell number in the mammalian gastrointestinal tract: the importance of apoptosis. **J. Cell Sci.** v. 107, p. 3569-77, 1994.

JUNQUEIRA, L. C.; CARNEIRO, J.; **Histologia básica**. Rio de Janeiro: Guanabara Koogan, 2013. 524p.

KARAM, S. M.; Cell lineage relationship in the stomach of normal and genetically manipulated mice. **Braz. J. Med. Biol. Res.** v. 31, p. 271-279, 1998.

KOH, T. J.; GOLDENRING, J. R.; ITO, S.; MASHIMO, H.; KOPIN, A. S.; VARRO, A.; DOCKRAY, G. J.; WANG, T. C.; Gastrin deficiency results in altered gastric differentiation and decreased colonic proliferation in mice. **Gastroenterology** v. 113, p. 1015-1025, 1997.

MORRIS, E. J.; DYSON, N. J.; Retinoblastoma protein partners. **Adv. Cancer Res.** v. 82, p. 1-54, 2001.

OFUSORI, D. A.; CAXTON-MARTINS, E. A.; A comparative histomorphometric study of the stomach of rat (*Rattus norvegicus*), bat (*Eidolon helvum*) and pangolin (*Manis tricuspis*) in relation to diet. **Int. J. Morphol.** v. 26, p. 669-674, 2008.

OWEN, D. A.; Stomach. In: **Histology for pathologists**. Philadelphia: Sternberg SS, 1997. p. 481-493.

PASSOS, J. F. **Neonatologia Veterinária**. Trabalho de conclusão do curso de medicina veterinária. 2006. 55f (Monografia) - Área de obstetrícia veterinária. União Pioneira de Integração Social, Brasília, 2006.

SATO, M.; AHNEN, D. J., Regional variability of colonocyte growth and differentiation in the rat. **Anat. Record.** v. 233, p. 409-414, 1992.

SOYBEL, D. I.; Anatomy and physiology of the stomach. **Surg. Clin. N. Am.** v. 85, p. 875-894, 2005.

ZHU, L.; ENDERS, G.; LEES, J. A.; BEIJERSBERGEN, R. L.; BERNARDS, R.; HARLOW, E.; The pRB-related protein p107 contains two growth suppression domains: independent interactions with E2F and cyclin/cdk complexes. **Embo. J.** v. 14, p. 1904-1913, 2005.